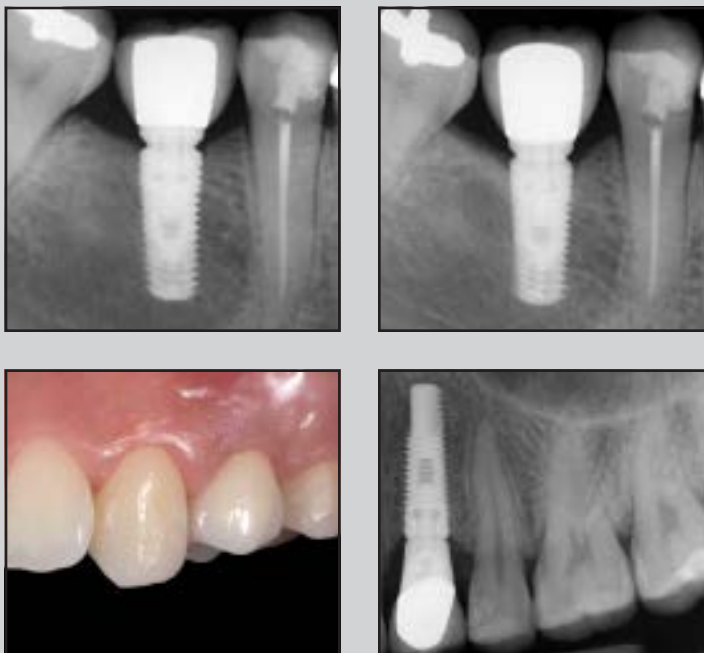




# Hybrid Implants in Healthy and Periodontally Compromised Patients: A Preliminary Clinical and Radiographic Study



Sergio Spinato, DDS<sup>1</sup>  
 Fabio Bernardello, DDS<sup>2</sup>  
 Paolo Sassatelli, MEng<sup>3</sup>  
 Davide Zaffe, MBiolSc<sup>4</sup>

*This preliminary clinical and radiographic study examined the survival of, the marginal bone loss (MBL) around, and the influence of prosthetic abutment height (AH) on MBL around hybrid implants placed in two groups of partially edentulous patients: healthy (HPs) and periodontally compromised (PCPs) patients. A total of 93 patients requiring single or multiunit implant restoration, in the mandible or maxilla, were treated while undergoing cement-retained prosthetic restoration. A total of 54 implants (35 in the maxilla and 19 in the mandible) were placed in 45 HPs, and 56 implants (31 in the maxilla and 25 in the mandible) in 48 PCPs. All 110 hybrid implants positioned in pristine bone provided a 100% survival rate in both HPs and PCPs. No statistical differences were recorded comparing the MBL values of maxillae with those of mandibles. In HPs and PCPs, a similar and limited amount of MBL was recorded, and it was found that the higher the AH, the less MBL. In conclusion, results indicate that the hybrid implants examined could reduce the risk of peri-implantitis due to their coronal machined surfaces and improve osseointegration due to their apical rough surfaces. Int J Periodontics Restorative Dent 2017;37:195–202. doi: 10.11607/prd.3140*

<sup>1</sup>Private Practice, Sassuolo, Italy.

<sup>2</sup>Private Practice, Terranegra di Legnago, Italy.

<sup>3</sup>PhD Student, Department of Engineering, University of Modena and Reggio Emilia, Modena, Italy.

<sup>4</sup>Associate Professor, Department of Biomedical, Metabolic and Neural Sciences, University of Modena and Reggio Emilia, Modena, Italy.

Correspondence to: Prof Davide Zaffe, Dipartimento di Scienze Biomediche, Metaboliche e Neuroscienze, Sezione di Morfologia Umana, Università di Modena e Reggio Emilia Via del pozzo 71, Policlinico, 41124 Modena MO, Italy. Fax: 0594224861.  
 Email: davide.zaffe@unimore.it

©2017 by Quintessence Publishing Co Inc.

Dental implant therapy has become more widely used in recent decades due to increasing overall success rates. A significant number of fully and partially edentulous patients receiving implants have lost teeth due to infective destruction and/or periodontal disease.<sup>1,2</sup> Selected patients sometimes presented modest oral hygiene standards around implant necks<sup>3</sup> or reduced compliance over time during supportive periodontal therapy.<sup>4</sup> As a consequence, a higher number of implants placed led to an increased number of infective complications and failure.<sup>5,6</sup>

In particular, many systematic reviews<sup>7,8</sup> and clinical trials<sup>4,9,10</sup> have suggested that implant failure and associated marginal bone loss (MBL) is greater in patients with a history of periodontitis. Although the precise nature of the relationship between periodontal disease and peri-implant infections has not been completely clarified,<sup>11</sup> microbiota-environmental factors have been identified in both situations.<sup>12</sup> Recent analyses have demonstrated no significant differences between bacterial genera on implants and teeth in supra- and subgingival biofilms. Diseased peri-implant and periodontal tissues shared similar microbiota.<sup>13</sup> In fact, in patients affected by periodontal disease, it has been demonstrated that periodontal pathogens can be transmitted from the periodontal pocket

to the peri-implant sulcus.<sup>12</sup> With a coronal rough surface implant, a bio-film of bacteria forms in and around the implant on exposure to the oral environment.<sup>14</sup> Because these microbiota may persist and proliferate on the implant surface, they can lead to peri-implantitis and consequent peri-implant bone loss.<sup>14</sup>

Therefore, debate continues as to whether implants with machined surfaces are less prone to bone loss due to peri-implantitis than implants with rough surfaces. In a retrospective study, Simion et al stated that the risk of peri-implantitis could be considered only a minor problem when machined implants are used.<sup>15</sup> On the contrary, hydroxyapatite and titanium plasma-spray surfaces promote a more rapid progression of peri-implantitis with consequent high failure rates<sup>16</sup> than machined surfaces, which reported a 20% reduction in the risk of being affected by peri-implant infections.<sup>17</sup> On the other hand, the survival rate of implants with rough surfaces is greater than that of implants with machined surfaces in augmented maxillary sinuses.<sup>18</sup>

Rough implant surfaces provided better clinical and histologic performances as demonstrated in human histologic and histomorphometric studies in which significantly greater bone-to-implant contact with rough surfaces was found in both pristine and grafted bone when compared with a machined surface.<sup>19,20</sup> In fact, modifications of machined surfaces via sandblasting and acid etching have been developed to create microtopographies that improve titanium implant healing in bone by means of a higher

rate and greater extent of adherent bone formation. Based on this premise, hybrid implants should include the advantages of machined surfaces in the coronal region, reducing the risk of peri-implantitis, and the biologic advantages of rough surfaces in the apical region, improving osseointegration. However, only a few short- and medium-term clinical evaluations have been carried out on these implants.<sup>21,22</sup>

MBL around implant necks has been used for many years as the principal criterion for evaluating long-term implant success.<sup>23</sup> Recently, it was demonstrated that prosthetic abutment height (AH), calculated as the distance from the implant platform to the apical edge of the crown, can significantly affect peri-implant bone stability.<sup>24</sup> These studies reported less MBL around implants with longer abutments than around those with shorter.<sup>24</sup>

The aim of this preliminary prospective study was to analyze the survival and marginal bone changes around new generation hybrid implants placed in two groups of partially edentulous patients: healthy (HPs) and periodontally compromised (PCPs) patients.

## Materials and Methods

A total of 93 consecutive partially edentulous patients requiring single or multiunit implant restoration, splinted with the same prostheses, in either the mandible or the maxilla, were independently examined and treated by two private dental operators (S.S. and F.B.) in two offices while


undergoing cement-retained prosthetic restoration.

Contrary to public and private health centers (DM 18/3/1998, published in the Official Gazette, GU n. 122 of 28-05-1998), Italian law does not require ethical committee approval for clinical work performed in private dental offices, and therefore no ethical committee resolution is released. Nevertheless, all patients signed informed consent in which all procedures of the study were detailed. All research was conducted in full accordance with ethical principles, including the 2008 Helsinki Declaration.<sup>25</sup>

Inclusion criteria for the study were as follows: at least 18 years of age, good general health, presence of adequate bone volume to achieve primary implant stability without concomitant or previous guided bone regeneration procedures of the alveolar crest, and at least 8 mm of basal bone height below the maxillary sinus or the mandibular canal.

Exclusion criteria were as follows: poor oral hygiene and motivation; smoking habits; active infection; absence of keratinized mucosa; lack of occlusal contacts with the opposing dentition; the presence of diseases affecting bone metabolism or wound healing; a history of head or neck radiation therapy; and regular medicinal consumption of steroids, tetracyclines, bisphosphonates, or other medication affecting bone turnover and patient pregnancy at any time during the study.

The clinical and radiographic diagnosis allowed patients to be split into two groups: HPs and PCPs. HPs revealed no clinical or radiographic



**Fig 1** Sequential views (a, b, and c) of a hybrid implant with a machine-surfaced coronal third and the apical two-thirds having a rough surface. SEM images of bottom of thread furrows: (M1) machined surface; (R1) rough surface.<sup>26</sup> The boxed areas of M1 and R1 correspond to areas analyzed by profilometer,<sup>26</sup> the 3D graphs of which are reported (far right): (M2) machined surface ( $R_a = 2.42 \pm 0.36$ ); (R2) rough surface ( $R_a = 0.53 \pm 0.11$ ).<sup>26</sup> Notice the different aspects of the two surface types.

signs of chronic periodontitis at the time of the first visit. However, they were instructed in oral hygiene before implant placement. PCPs exhibited clinical and radiographic signs of chronic periodontitis and were therefore treated with nonsurgical therapy: supragingival debridement, scaling, and root planing. To eliminate infections and reduce the periodontal pocket depth, surgical periodontal therapy was performed when it was considered necessary at patient re-evaluation. Nevertheless, residual pockets > 3 mm in depth were still present at the end of periodontal treatment in few cases.

To evaluate the crestal bone width and height and sinus health of all patients, cone beam computed tomography scans were taken before surgery.

### *Implant Placement and Prosthetic Delivery*

A two-stage protocol was used following the manufacturer's recommendation: the implant site was prepared to allow crestal positioning of the implant neck. After full-thickness flap opening under local anesthesia, the implant location was marked using a small-diameter pilot drill, and a prefabricated surgical guide was used to work through the cortical bone. All implants (Shape1-Hybrid, i-RES) (Fig 1) were submerged. After postoperative antibiotic and germicidal mouthrinse treatment, sutures were removed 12 to 14 days after surgery. Patients used no removable prostheses during the healing period. The time

between implant placement and exposure was 3 to 4 months. Healing abutments were placed during this second surgical phase, and implant-supported cemented prostheses were delivered approximately 4 weeks later. The height of the customized titanium abutments used to connect crown to implant were individually chosen for each patient to obtain optimal crown retention and an acceptable esthetic emergence profile. The finished abutments were torqued to 30 Ncm, and all single- and multiple-tooth definitive metal-porcelain restorations were delivered and cemented. During the cementing phase, particular care was taken to remove excess cement from the soft tissue. A professional oral hygiene maintenance protocol was performed every 4 months.

### *Clinical Soft Tissue Evaluation*

To assess mucosal health around implant necks, bleeding on probing, suppuration, and probing depth were evaluated 6 months and 1 year after implant functionalization. In the presence of bleeding on probing, suppuration, or probing depths exceeding 5 mm at the 6-month follow-up appointment, radiographs were taken to evaluate peri-implant bone loss. In the absence of these clinical signs, radiographs were taken at the 1-year final check-up.

### *Radiography*

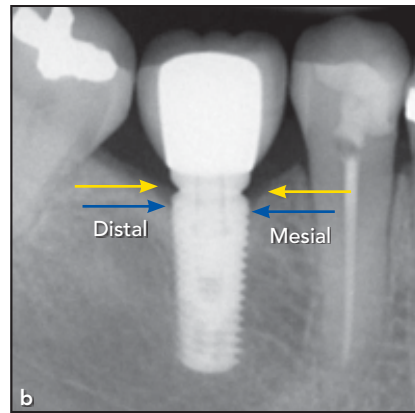
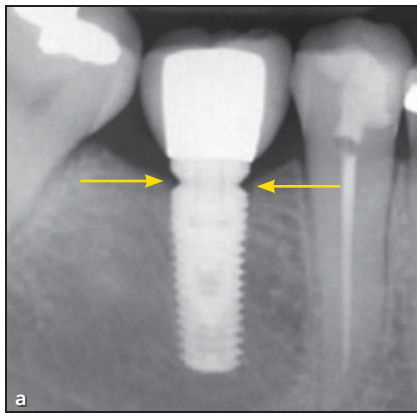
To ensure standardization of measurements, digital radiographs were

taken using a long-cone paralleling technique with a Rinn-type film holder at the time of surgical implant placement, at final prosthetic restoration delivery (baseline), and at 12 months after prosthetic loading. A phantom (implant + abutment + restoration, embedded in transparent polyester resin) was preliminarily used to calibrate both x-ray machines. MBL was calculated by linear measurements taken from the most mesial and most distal points of the implant platform to the crestal bone on each radiograph and were calibrated in reference to the known height and diameter of each implant. MBL was calculated as mesial and distal bone changes at the 12-month follow-up visit (Fig 2). AH was calculated by linear measurements taken from the most mesial and most distal points of the implant platform to the most mesial and most distal points of the apical edge of the cemented crown (Fig 3). Radiographs showing signs of deformation, darkness, or other complications were retaken. Measurements were performed to the nearest 0.01 mm using Kodak Digital Imaging Software (Eastman Kodak) by a single independent calibrated examiner (D.Z.).

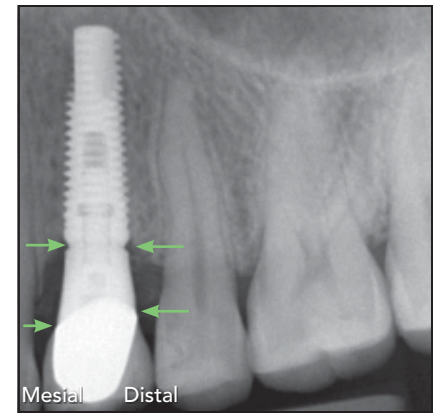
### *Statistical Analysis*

*Primer of Biostatistics* was used for statistical analysis.<sup>27</sup> Comparisons were performed by means of one-way analysis of variance. The null hypothesis H<sub>0</sub> was rejected for a critical significance level of  $P < .05$ .





**Fig 2** (a) Baseline. Marginal bone loss (MBL) is calculated as mesial and distal bone change at the (b) 12-month follow-up.



**Fig 3** Abutment height (AH) is calculated at baseline from the most mesial and distal points of the implant platform to the most mesial and distal points of the apical edge of the crown.

**Table 1** Sex, Age, and AH of Patient Groups

	Group 1			Group 2			Group 3		
	HPs	PCPs	<i>P</i>	HPs	PCPs	<i>P</i>	HPs	PCPs	<i>P</i>
Sex									
M	5	8		12	12		8	8	
F	4	7		7	7		9	6	
Age (y)	56.9 ± 14.5	60.4 ± 7.7	.44	53.1 ± 11.1	59.6 ± 9.5	.06	52.2 ± 14.0	61.1 ± 11.1	.06
Mesial AH (mm)	1.35 ± 0.19	1.36 ± 0.22	.91	1.97 ± 0.29	1.99 ± 0.31	.83	2.82 ± 0.61	2.69 ± 0.42	.47
Distal AH (mm)	1.35 ± 0.26	1.36 ± 0.26	.92	1.96 ± 0.30	2.05 ± 0.31	.28	2.85 ± 0.56	2.69 ± 0.42	.88

Analysis of variance.

HPs = healthy patients; PCPs = periodontally compromised patients; AH = abutment height.

## Results

A total of 54 implants were placed in 45 healthy patients (HPs) and 56 implants in 48 periodontally compromised patients (PCPs). All 110 implants placed were functioning at the 1-year follow-up for a 100% survival rate. Of these, 80 were single-unit implant restorations, 18 were two-unit fixed restorations, and 12 were three-unit implant restorations. In HPs, 35 implants were placed in the maxilla and 19 in the mandible, while 31 implants were placed in

the maxilla and 25 in the mandible of PCPs. No statistically significant differences ( $P > .05$ ) were recorded between the maxilla and mandible in terms of mesial and distal MBL.

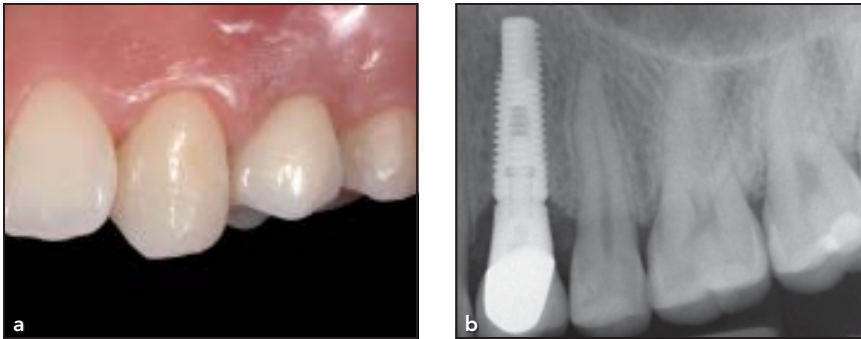
Nonsurgical and surgical periodontal treatment of PCPs was uneventful. Six months after loading, four implants (two in PCPs and two in HPs) with prosthetic AH less than 1.6 mm reported bleeding on probing and suppuration indicative of mucositis. Radiographs completely excluded bone loss around implants. After the removal of excess cement,

complete healing was obtained in all four cases. No further complications were described. After 1 year, no probing depth exceeded 5 mm.

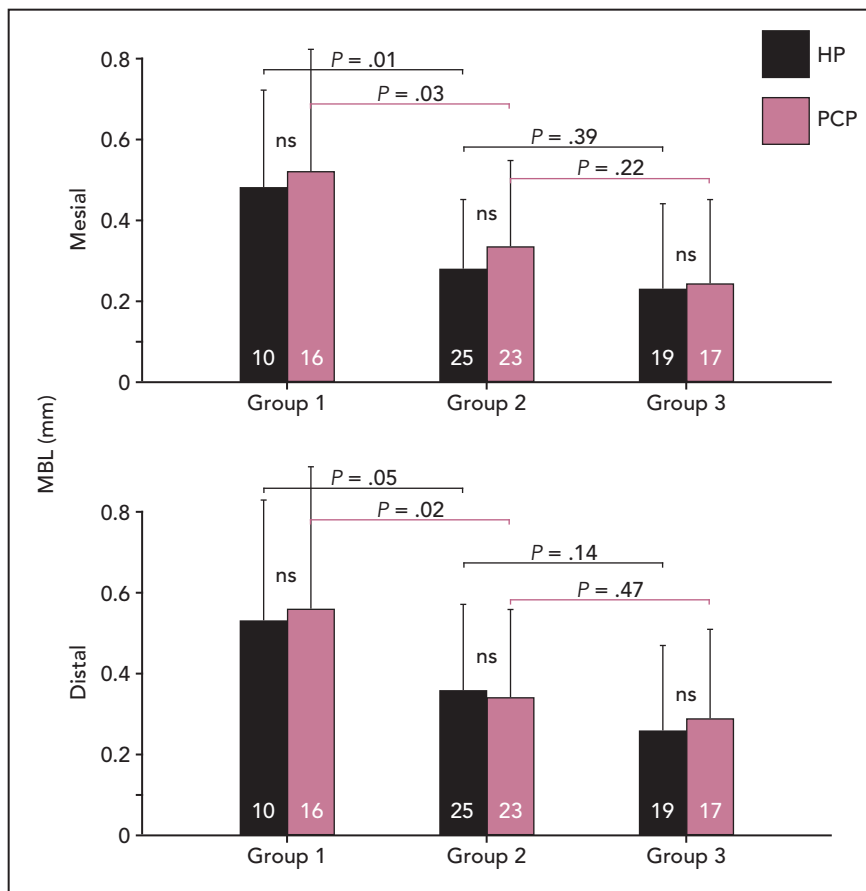
HPs and PCPs of both sexes, aged between 31 and 84 years (Table 1), were subdivided into three groups based on mean AH<sup>24</sup>:

- Group 1: AH < 1.6 mm
- Group 2: AH 1.6–2.4 mm
- Group 3: AH > 2.4 mm (Fig 4)

No statistically significant differences ( $P > .05$ ) were recorded



**Fig 4** Clinical (a) and radiographic (b) outcome after 12 months. Note that crestal bone is very stable in the presence of a high prosthetic abutment.



**Fig 5** Behavior of MBL ( $m + SD$ ) in group 1 (AH < 1.6 mm), group 2 (AH 1.6–2.4 mm) and group 3 (AH > 2.4 mm) healthy (HP) and periodontally compromised (PCP) patients, at the mesial and distal aspects. The number of abutments (frequency) pertaining to each group is reported in each column. No significant differences (ns) ( $P > .05$ ) were detected within each group, while comparisons between group 1 and group 2 values were always statistically significant (analysis of variance). On the contrary, all comparisons between group 2 and group 3 values were not significant ( $P > .05$ ).

comparing HP and PCP subgroups of each group for age, mesial AH, or distal AH (Table 1). Similarly, in comparing MBL in the maxillae and mandibles of HP and PCP subgroups of each group, no statistically significant differences ( $P > .05$ ) were recorded.

The statistical analyses of the MBL of groups 1 (AH < 1.6 mm), 2 (AH 1.6–2.4 mm), and 3 (AH > 2.4 mm) highlight the absence of differences ( $P > .05$ ) between the HP and PCP subgroups for both mesial and distal MBL (Fig 5). In both HP and PCP subgroups, the

mean value of the mesial and distal MBL of group 1 was approximately 0.5 mm. This value dropped to approximately 0.35 mm in group 2, and approximately 0.25 mm in group 3, for both HP and PCP subgroups (Fig 5). In both HP and PCP subgroups, the value of mesial and

distal MBL of group 1 was significantly greater than the corresponding value of group 2. No statistically significant difference was found, however, when comparing the lower values of group 2 with those of group 3 (Fig 5).

## Discussion

Several studies<sup>4,7-10</sup> showed that implants placed in PCPs had lower survival rates and higher MBL rates compared with implants placed in HPs.

In the present clinical and radiographic evaluation of hybrid implants, no failure was recorded in either HPs or PCPs. The mean MBL around implants placed in PCPs was the same as that around implants placed in HPs. This positive outcome may be related to several factors: first, nonsurgical and surgical periodontal treatment before implant placement and high level of oral hygiene during the following year certainly may have contributed to the reduction of both microbiota and periodontal infection.<sup>12-14</sup> Additionally, the machined surface of the coronal part of these implants has been demonstrated to be less susceptible to peri-implantitis than rough surfaces.<sup>15,17</sup> Moreover, a recent histologic study has stated that osseointegration follows a similar healing pattern with machined and rough implant surfaces.<sup>28</sup> This could mean that implant surface characteristics do not affect the bone remodeling phase subsequent to surgical trauma.

One of the most important criteria in evaluating long-term im-

plant success is the MBL rate.<sup>23</sup> In a 5-year comparison between traditional fully rough-surface and hybrid-surface implants, MBL was statistically less for fully rough implants than for hybrid implants.<sup>22</sup> However, in the aforementioned study only nonplatform-switched implants with an external connection were examined. It is well-established that MBL levels are more strongly related to platform-switching design and to the type of connection—the former (platform-switching design) limits crestal bone loss,<sup>29</sup> whilst the latter (external connection) promotes greater bone loss than an internal connection.<sup>23</sup> In this study, only hybrid implants with a platform-switching design and internal connection were placed to limit MBL. Therefore, the comparison between traditional fully rough-surface and hybrid-surface implants has not been investigated.

A recent study showed that implants with MBL greater than 0.44 mm at 6 months had 33 times the risk of peri-implant bone progression over time.<sup>23</sup> In the present investigation, the mean amount of MBL was 0.5 mm in the presence of short prosthetic abutments (lower than 1.6 mm—group 1), while this mean amount was reduced to 0.35 mm in the presence of a longer abutment (1.6 to 2.4 mm) and even reduced to 0.25 mm with an abutment height greater than 2.4 mm (group 3). This means that the ideal distance from the prosthetic restoration to the bone crest to limit bone loss may be 2 mm or more, since only enough vertical space could enable

biologic processes providing width re-establishment around the abutment. These findings are in close agreement with Galindo-Moreno et al, who demonstrated the same on multiunit-implant screw-retained prostheses.<sup>24</sup> Therefore, the present study demonstrates that the shorter the abutment height, the greater the MBL around both single- and multiunit-implant cement-retained restorations. As a consequence, the use of high abutments to connect cemented prostheses to implants provides not only greater height for biologic width re-establishment, but also easier excess cement removal from soft tissue to prevent mucositis and peri-implantitis.<sup>30</sup>

## Conclusions

Within the limitations of this study, the following conclusions can be drawn: (1) hybrid implants in both PCPs and HPs provided a 100% survival rate in pristine bone; (2) the recorded amount of MBL was very contained and, surprisingly, similar in both PCPs and HPs; and (3) the higher the prosthetic abutment height, the less MBL around implants with cement-retained prostheses.

Long-term studies on hybrid implants are needed to confirm or refute these findings.

## Acknowledgments

The authors reported no conflicts of interest related to this study.



## References

1. Klinge B, Flemming T, Cosyn J, et al. The patient undergoing implant therapy. Summary and consensus statements. The 4th EAO Consensus Conference 2015. *Clin Oral Implants Res* 2015; 26(suppl 11):64–67.
2. Hultin M, Gustafsson A, Hallström H, Johansson LA, Ekfeldt A, Klinge B. Microbiological findings and host response in patients with peri-implantitis. *Clin Oral Implants Res* 2002;13:349–358.
3. Serino G, Ström C. Peri-implantitis in partially edentulous patients: Association with inadequate plaque control. *Clin Oral Implants Res* 2009;20:169–174.
4. Rocuzzo M, De Angelis N, Bonino L, Aglietta M. Ten-year results of a three-arm prospective cohort study on implants in periodontally compromised patients. Part 1: implant loss and radiographic bone loss. *Clin Oral Implants Res* 2010;21:490–496.
5. Quirynen M, De Soete M, van Steenberghe D. Infectious risks for oral implants: A review of the literature. *Clin Oral Implants Res* 2002;13:1–19.
6. Lindhe J, Meyle J. Peri-implant diseases: Consensus Report of the Sixth European Workshop on Periodontology. *J Clin Periodontol* 2008;35(8 suppl):282–285.
7. Heitz-Mayfield LJ. Peri-implant diseases: Diagnosis and risk indicators. *J Clin Periodontol* 2008;35(8 suppl):292–304.
8. Renvert S, Persson GR. Periodontitis as a potential risk factor for peri-implantitis. *J Clin Periodontol* 2009;36(suppl 10):9–14.
9. Mengel R, Behle M, Flores-de-Jacoby L. Osseointegrated implants in subjects treated for generalized aggressive periodontitis: 10-year results of a prospective, long-term cohort study. *J Periodontol* 2007;78:2229–2237.
10. Matarasso S, Rasperini G, Iorio Siciliano V, Salvi GE, Lang NP, Aglietta M. A 10-year retrospective analysis of radiographic bone-level changes of implants supporting single-unit crowns in periodontally compromised vs. periodontally healthy patients. *Clin Oral Implants Res* 2010;21:898–903.
11. Dereka X, Mardas N, Chin S, Petrie A, Donos N. A systematic review on the association between genetic predisposition and dental implant biological complications. *Clin Oral Implants Res* 2012; 23:775–788.
12. Sumida S, Ishihara K, Kishi M, Okuda K. Transmission of periodontal disease-associated bacteria from teeth to osseointegrated implant regions. *Int J Oral Maxillofac Implants* 2002;17:696–702.
13. Schaumann S, Staufienbiel I, Scherer R, et al. Pyrosequencing of supra- and subgingival biofilms from inflamed peri-implant and periodontal sites. *BMC Oral Health* 2014;14:157.
14. Berglundh T, Gislason O, Lekholm U, Sennerby L, Lindhe J. Histopathological observations of human periimplantitis lesions. *J Clin Periodontol* 2004;31: 341–347.
15. Simion M, Gionso L, Grossi GB, Briguglio F, Fontana F. Twelve-year retrospective follow-up of machined implants in the posterior maxilla: Radiographic and peri-implant outcome. *Clin Implant Dent Relat Res* 2015;17(suppl 2):e343–e351.
16. Hanisch O, Cortella CA, Boskovic MM, James RA, Slots J, Wikesjö UM. Experimental peri-implant tissue breakdown around hydroxyapatite-coated implants. *J Periodontol* 1997;68:59–66.
17. Esposito M, Ardebili Y, Worthington HV. Interventions for replacing missing teeth: Different types of dental implants. *Cochrane Database Syst Rev* 2014; 7:CD003815.
18. Del Fabbro M, Testori T, Francetti L, Weinstein R. Systematic review of survival rates for implants placed in the grafted maxillary sinus. *Int J Periodontics Restorative Dent* 2004;24:565–577.
19. Trisi P, Lazzara R, Rao W, Rebaudi A. Bone-implant contact and bone quality: Evaluation of expected and actual bone contact on machined and osseointegrated implant surfaces. *Int J Periodontics Restorative Dent* 2002;22:535–545.
20. Trisi P, Marcato C, Todisco M. Bone-to-implant apposition with machined and MTX microtextured implant surfaces in human sinus grafts. *Int J Periodontics Restorative Dent* 2003;23:427–437.
21. Lee SY, Piao CM, Koak JY, et al. A 3-year prospective radiographic evaluation of marginal bone level around different implant systems. *J Oral Rehabil* 2010;37: 538–544.
22. Zetterqvist L, Feldman S, Rotter B, et al. A prospective, multicenter, randomized-controlled 5-year study of hybrid and fully etched implants for the incidence of peri-implantitis. *J Periodontol* 2010; 81:493–501.
23. Galindo-Moreno P, León-Cano A, Ortega-Oller I, Monje A, O'Valle F, Catena A. Marginal bone loss as success criterion in implant dentistry: Beyond 2 mm. *Clin Oral Implants Res* 2015;26:e28–e34.
24. Galindo-Moreno P, León-Cano A, Ortega-Oller I, et al. Prosthetic abutment height is a key factor in peri-implant marginal bone loss. *J Dent Res* 2014;93 (7 suppl):80S–85S.
25. Puri KS, Suresh KR, Gogtay NJ, Thattai UM. Declaration of Helsinki, 2008: Implications for stakeholders in research. *J Postgrad Med* 2009;55:131–134.
26. Bertoldi C, Lusuardi D, Battarra F, Sassetelli P, Spinato S, Zaffe D. The maintenance of inserted titanium implants: In-vitro evaluation of exposed surfaces cleaned with three different instruments [ePub ahead of print 7 Jan 2016]. *Clin Oral Implants Res* doi: 10.1111/clr.12759.
27. Glantz SA. *Primer of Biostatistics*, ed 6. New York: McGraw Hill, 2005.
28. Simion M, Benigni M, Al-Hezaimi K, Kim DM. Early bone formation adjacent to oxidized and machined implant surfaces: A histologic study. *Int J Periodontics Restorative Dent* 2015;35:9–17.
29. Canullo L, Fedele GR, Iannello G, Jepsen S. Platform switching and marginal bone-level alterations: The results of a randomized-controlled trial. *Clin Oral Implants Res* 2010;21:115–121.
30. Wilson TG Jr. The positive relationship between excess cement and peri-implant disease: A prospective clinical endoscopic study. *J Periodontol* 2009;80: 1388–1392.

Copyright of International Journal of Periodontics & Restorative Dentistry is the property of Quintessence Publishing Company Inc. and its content may not be copied or emailed to multiple sites or posted to a listserv without the copyright holder's express written permission. However, users may print, download, or email articles for individual use.